

EXPERIENCE OF USING PHOTODYNAMIC THERAPY IN THE TREATMENT OF ESOPHAGEAL CANCER

Tumanina A.N.¹, Polezhaev A.A.³, Apanasevich V.A.³, Gurina L.I.¹, Volkov M.V.¹, Tarasenko A.Yu.¹, Filonenko E.V.²

¹FSBI HE Pacific State Medical University of the Ministry of Health of the Russian Federation, Vladivostok, Russia

²P.A. Herzen Moscow Oncology Research Center – branch of FSBI NMRRC of the Ministry of Health of the Russian Federation, Moscow, Russia

³Primorsky Regional Oncology Center, Vladivostok, Russia

Abstract

Photodynamic therapy (PDT) is a worthy alternative to surgical esophageal resection or endoscopic mucosal resection and dissection (EMR, ESD) in patients with superficial esophageal cancer with severe concomitant diseases as well as in patients with a common form of esophageal cancer with severe malignant dysphagia. Patients with superficial (7) and advanced (15) esophageal cancer received PDT as an independent method and as a supplement to complex treatment. Radachlorin was used as a photosensitizer at a dose of 0.6–0.8 mg/kg, administered intravenously 3 hours before irradiation. A PDT session was carried out using a laser with a wavelength of 662 nm. The light dose used was 150–300 J/cm². The use of PDT made it possible to achieve the full effect in 7 (100%) patients in the group of superficial (T1a-T1b) esophageal cancer where PDT was either the only method of treatment or in combination with radiation therapy. In the group of patients with stenotic cancer the use of PDT made it possible to achieve full recovery of food intake after recanalization for 20% of patients, and partial – for 66.7%. Thus, complete natural food intake was restored for 86.7% of patients which improved their quality of life. PDT is also a method of choice for cancer of the upper esophagus as esophageal stenting in this situation can cause unwanted subjective sensations.

Key words: photodynamic therapy, esophageal cancer, radachlorin,

For citations: Tumanina A.N., Polezhaev A.A., Apanasevich V.A., Gurina L.I., Volkov M.V., Tarasenko A.Yu., Filonenko E.V. Experience of using photodynamic therapy in the treatment of esophageal cancer, *Biomedical Photonics*, 2019, vol. 8, no. 2, pp. 19–24. (in Russian) doi: 10.24931/2413–9432–2019–8–2–19–24

Contacts: Tumanina A.N., e-mail: tumanina.a.n@mail.ru

ОПЫТ ПРИМЕНЕНИЯ ФОТОДИНАМИЧЕСКОЙ ТЕРАПИИ В ЛЕЧЕНИИ РАКА ПИЩЕВОДА

А.Н. Туманина¹, А.А. Полежаев³, В.А. Апанасевич³, Л.И. Гурина¹, М.В. Волков¹, А.Ю. Тарасенко¹, Е.В. Филоненко²

¹ФГБОУ ВО «Тихоокеанский государственный медицинский университет» Минздрава России, Владивосток, Россия

²МНИОИ им. П.А. Герцена – филиал ФГБУ «НМИЦ радиологии» Минздрава России, Москва, Россия

³Приморский краевой онкологический диспансер, Владивосток, Россия

Резюме

Фотодинамическая терапия (ФДТ) является достойной альтернативой хирургической резекции пищевода и эндоскопической резекции или диссекции слизистой (EMR, ESD) у пациентов с поверхностным раком пищевода при наличии у них тяжелых сопутствующих заболеваний, а также у пациентов с распространенной формой рака пищевода при выраженной злокачественной дисфагии. Больные поверхностным (7 человек) и стенозирующим (15 человек) раком пищевода получали ФДТ в качестве самостоятельного лечения, а также в качестве дополнения к комплексной терапии. В качестве фотосенсибилизатора применяли препарат радахлорин в дозе 0,6–0,8 мг/кг, который внутривенно вводили пациентам за 3 ч до начала облучения. Сеанс ФДТ проводили с использованием лазера с длиной волны 662 нм. Световая доза составила 150–300 Дж/см². Применение ФДТ позволило достичь полного эффекта у 7 (100%) пациентов в группе с поверхностным (T1a-T1b) раком пищевода, где ФДТ применяли как единственный метод лечения или в сочетании с лучевой терапией. В группе пациентов со стенозирующим раком с помощью ФДТ удалось добиться полного восстановления питания после реканализации у 20% больных, частичного – у 66,7%. Таким образом, у 86,7% пациентов было восстановлено полноценное естественное питание, что значительно улучшило качество их жизни. ФДТ является методом выбора при лечении злокачественных

новообразований верхних отделов пищевода, так как стентирование пищевода в данной ситуации может вызвать нежелательные субъективные ощущения.

Ключевые слова: фотодинамическая терапия, рак пищевода, радахлорин.

Для цитирования: Туманина А.Н., Полежаев А.А., Апанасевич В.А., Гурина Л.И., Волков М.В., Тарасенко А.Ю., Филоненко Е.В. Опыт применения фотодинамической терапии в лечении рака пищевода // Biomedical Photonics. – 2019. – Т. 8, № 2. – С. 19–24. doi: 10.24931/2413-9432-2019-8-2-19-24

Контакты: Туманина А.Н., e-mail: tumanina.a.n@mail.ru

Introduction

Esophageal cancer (EC) is a difficult to treat disease that ranks the 8th in the structure of cancer morbidity in the world and the 6th in the structure of cancer mortality [1]. Despite the development of new diagnostic and treatment methods for esophageal cancer at the early stages in recent years, the frequency of detecting patients with EC at the third and fourth stages is still very high accounting for 67% [2]. An important indicator of the esophageal cancer malignancy is low 5-year survival rates, not exceeding 10–15% both in Russia and European countries [3]. In half of the cases, the main clinical symptom of esophageal cancer is dysphagia occurring when the lumen is narrowed by 50–70% [4] and limiting the possibilities of surgical, radiation, combination and comprehensive treatment [1, 2, 5]. In addition, there is a large group of patients (up to 25%) that cannot undergo curative surgery due to the presence of severe coexisting diseases and age-related changes [5]. Radiation therapy (RT) is an EC treatment method chosen for this patient population, however, in this case there is a high probability of the disease recurrence with the development of stenosis. Furthermore, the second course of RT is impossible after irradiation at doses corresponding to a curative treatment regimen [6]. Endoscopic treatment is increasingly used for these reasons. Endoscopic mucosa resection (EMR) and endoscopic submucosa dissection (ESD) are current standards of treatment for superficial esophageal cancer, especially when it is spreads within the mucosa [7]. However, when annular lesions spread to more than two thirds of the circumference of the esophagus, these techniques (EMR and ESD) are not recommended due to the high risk of persistent esophageal stricture formation after the therapy [7, 8]. Another urgent problem is the development of endoscopic methods for dysphagia resolution, allowing to restore oral alimentation and enhance the quality of life of patients with stenotic esophageal cancer [8, 9]. Currently, minimally invasive endoscopic technologies (dilatation, recanalization caused by exposure to electrolaser destruction, argon plasma coagulation or photodynamic therapy) and endoprosthesis replacement are the most promising methods [3, 5].

The possibilities of modern oncology have greatly expanded with the advent of photodynamic therapy (PDT). This is a unique two-component treatment method based on the use of photosensitizers (PS) activated by light [10, 11]. Photosensitizers accumulate in a malignant tumor and stay in it for a longer time than in healthy tissues. Under local laser irradiation with light of a certain wavelength (at the PS absorption peak), a photochemical reaction begins in the tumor forming singlet oxygen and oxygen free radicals, which have a toxic effect on malignant cells [4, 6, 7, 12, 13]. PDT is an alternative method of treating patients with stenotic esophageal cancer as well as patients with superficial malignant tumors of this localization that have contraindications to curative treatment.

Materials and methods

This article is based on a study, which was conducted in compliance with the provisions of the Declaration of Helsinki (1964, revised in 2013). The study was conducted with the approval of the Institutional Control Ethics Commission. The form of the informed consent to endoscopic manipulations, including PDT, was also approved at the meeting of the above. Patients were informed about the PDT method, its benefits and possible risks, treatment regimen and duration of hospitalization and follow-up examinations. All patients signed the informed consent before the treatment.

From 2015 to 2017, endoscopic photodynamic therapy was conducted in 22 patients with esophageal cancer. The patients were divided into two groups. The first one included 7 patients with superficial esophageal cancer (T1a,bN0M0) that refused surgical treatment or had a severe comorbidity or a residual tumor of esophagus after RT. PDT was used as a curative treatment method in this group. The second group included 15 patients with locally advanced esophageal cancer who received PDT as palliative care to enhance the quality of their life and increase their life expectancy. The condition for the use of PDT was the absence of deep carcinelcrosis and an esophageal mediastinal or esophageal respiratory fistula. Men prevailed in both groups: the first group consisted of 5 men and 2 women, the second one included 15

men. The age of patients ranged from 47 to 76 years old and averaged 58 years old. In all cases, the squamous cell carcinoma was morphologically confirmed. Before the treatment, a four-degree scale of A.I. Savitsky was used to evaluate dysphagia:

the 1st degree of dysphagia is difficulty in swallowing solid food;

the 2nd degree of dysphagia is difficulty in swallowing semiliquid food;

the 3rd degree of dysphagia is difficulty in swallowing liquid food;

the 4th degree of dysphagia is difficulty in swallowing water, saliva.

In the first group of patients, no cases of dysphagia were detected; in the second one, there were the 2nd and the 3rd degrees of dysphagia. The lesion size varied: it ranged from 2 to 5 cm in patients of the first group and was up to 7 cm in patients of the second group. Localization of malignant esophageal tumors and tumor-induced stenosis was distributed as follows: in the middle third of the esophagus in 5 patients (71.4%) and in the lower third of the esophagus in 2 patients (28.6%) of the first group; in the upper third of the esophagus in 6 patients (40%), in the middle third of the esophagus in 8 patients (53.3%) and in the lower third of the esophagus in 1 patient (6.7%) of the second group. In the first group, PDT was used as an independent treatment method due to the presence of contraindications to curative surgical treatment or refusal of it in 3 (42.8%) patients or for the purpose of residual tumor destruction after RT in 4 (57.2%) patients. In the second group, PDT and subsequent endoprosthesis replacement (stenting) were conducted in 10 (66.7%) patients with the 3rd degree of dysphagia to recanalize tumor-induced stenosis. PDT was also conducted in 5 (33.3%) patients as an independent treatment method due to high location of tumors and inability to place a stent.

Before PDT, radachlorin (RADA-PHARMA LLC, Russia, registration licence No. LS-001868 of 16.12.2011) was administered to a patient via IV infusion at a dose of 0.6–0.8 mg/kg in a darkened room. A PDT session was conducted 3 hours after the PS administration using a laser with a wavelength of 662 nm (BIOSPEC LLC, Russia). A light dose was 150–300 J/cm². Irradiation was delivered to the site of exposure through a gastroscope channel. A quartz light guide was passed through an endoscope to a distal edge of the tumor, after which polypositional laser irradiation of the tumor was carried out. Quartz light guides with cylindrical diffusers and lengths of 1 to 5 m were used. The irradiation dose was selected individually depending on the tumor localization and size and the degree of esophagus narrowing. The number of irradiation positions ranged from 1 to 3. The total time of the polypositional irradiation of the tumor was from 10 to 40 minutes.

To prevent skin phototoxicity after endoscopic PDT, all patients were recommended to observe the light regime, involving limited exposure to the sun for 2 days and pain relief for 4 days if necessary. Follow-up esophagogastroduodenoscopy (EGD) was performed in the patients on the 4th day, then after 1 month and every 3 months after the PDT session. Computed tomography (CT) of the thoracic cavity was repeated every 3 months. In the presence of residual tumors, another PDT course was conducted 3–4 weeks after the previous one. Adverse events were evaluated during the first four days on the basis of patient complaints (pain behind the sternum, fever), visual examination and follow-up EGD performed on the 4th day and 1 month after the photodynamic therapy. The pain was assessed on a 10-point analogue scale and did not exceed 2–3 points on the 4th day. Intoxication syndrome was evaluated on the basis of patient complaints and data on fever. The PDT efficiency and the possibility of stenosis development were evaluated during esophagoscopy.

Results and discussion

The short-term treatment outcomes were evaluated on the 4th or 5th day after the first PDT course. During this period, demarcation of a necrotic zone and partial sloughing in a recanalization zone occurred, local inflammatory reaction remitted (Fig. 1).

In the first group, complete tumor regression was achieved in all patients as a result of PDT. With the full effect observed in 7 (100%) patients, unchanged mucosa was visible in 4 (57.2%) patients and scars were visible in 3 (42.8%) patients during the follow-up endoscopic examination. The absence of lesion growth signs was detected using a biopsy of the former tumor site and chromoendoscopy with a 1% Lugol's iodine solution.

The median follow-up of patients with superficial esophageal cancer was 28 months after the treatment. Progression in the form of distant metastases and local recurrence was diagnosed in only one patient who therefore underwent stent placement. The result was achieved in all 7 (100%) patients. In 2 (28.5%) patients with residual tumors after RT and achieving the full effect of PDT, cicatricial esophageal strictures of the 2nd degree were developed, which were successfully eliminated by means of endoscopic bougienage.

In the second group of patients, the effect was evaluated as complete and partial esophageal lumen restoration. The restoration of esophageal lumen was considered complete when it reached the diameter of 1 cm or more after recanalization (Fig. 2). Moreover, in the case of the complete esophageal lumen recanalization, an endoscope with a diameter of 9–12 mm smoothly reached the stomach. The complete esophageal lumen recanalization allowing patients to swallow almost any food was detected in 3 (20%) patients. The treatment effect in this

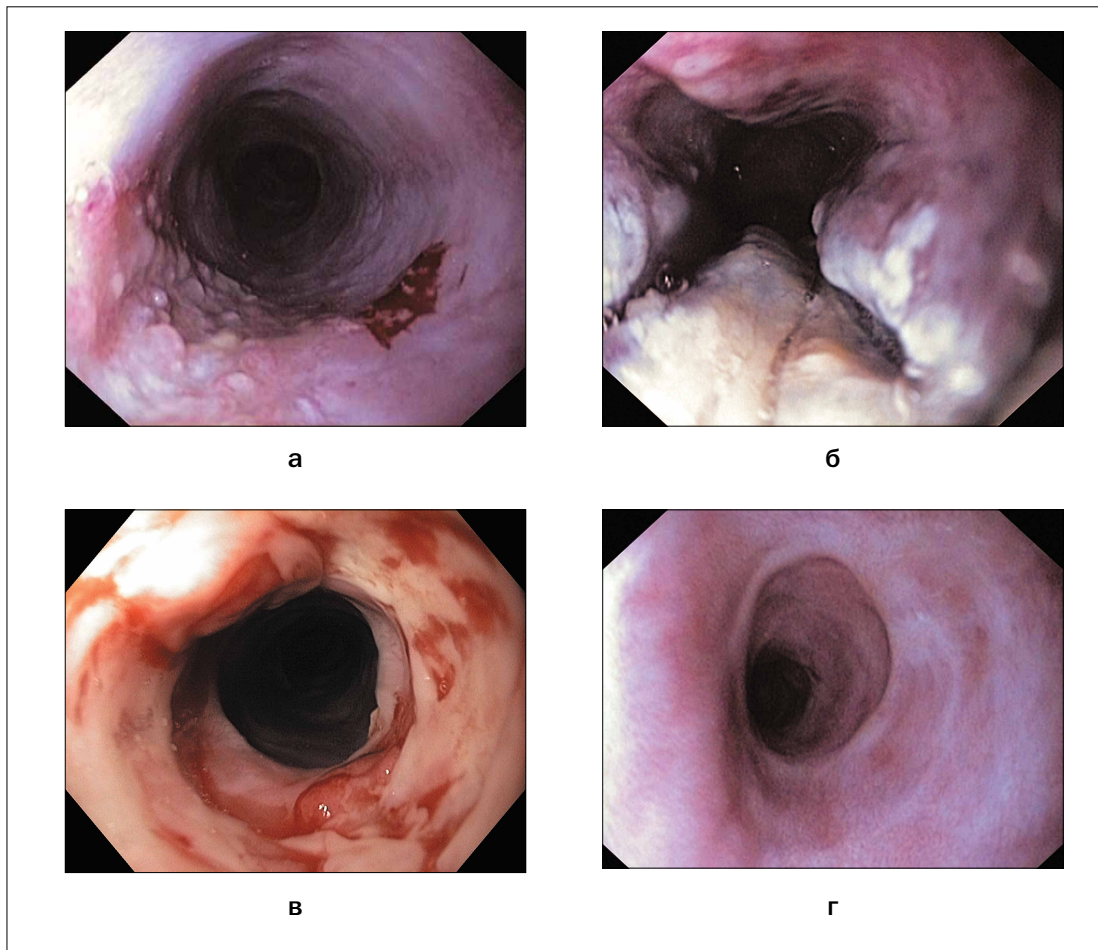


Рис. 1. Эндософотграфии локализованной формы рака пищевода в различные сроки после ФДТ:

- а – до проведения ФДТ;
- б – 4-ые сутки после ФДТ;
- в – через 1 мес после ФДТ;
- г – через 30 мес после ФДТ

Fig. 1. Endophotographs of a localized form of esophageal cancer at various times after PDT:

- a – before PDT;
- б – 4th day after PDT;
- в – 1 month after PDT;
- г – 30 months after PDT

patient population was supported by multi-course PDT. During the study, one patient underwent a maximum of 6 PDT courses. Average survival duration of this patient population was 28.2 months.

The partial esophageal lumen restoration after PDT was observed in 10 (66.7%) patients. The restoration of esophageal lumen was considered partial if its diameter did not exceed 0.6–0.8 after recanalization. In addition, an endoscope could be only passed beyond the area of tumor-induced stenosis constrainedly or after an additional bougienage procedure. After partial recanalization, patients could swallow semiliquid or liquid food, which corresponded to the 2nd and the 3rd degrees of dysphagia. This group included patients with tumors located in the upper third of the esophagus and those who underwent PDT for recanalization before stent place-

ment. Average survival duration of this patient population was 10.2 months.

The esophageal lumen recanalization procedure was not effective in 2 (13.3%) patients of the second group: after PDT and subsequent thermal destruction, the diameter of the esophagus remained the same, an endoscope could not be passed distal of stenosis, the patients' ability to swallow food did not change. This group included patients with tumor-induced stenosis of the upper third of the esophagus with extension to the larynx.

Conclusion

Thus, PDT is a valid alternative to surgical resection of the esophagus or endoscopic mucosa resection (EMR, ESD) in patients with superficial esophageal cancer having severe coexisting diseases as well as in patients with

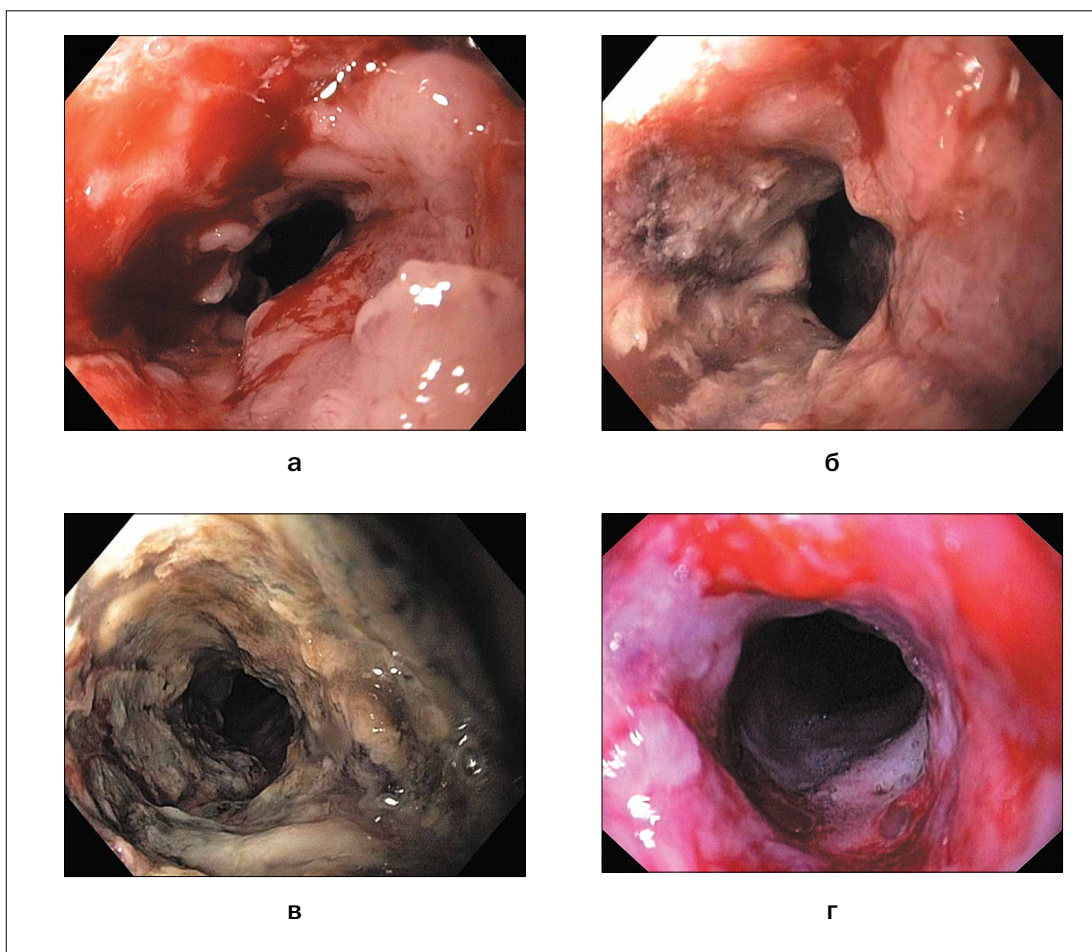


Рис. 2. Эндофотографии опухолевого стеноза пищевода в различные сроки после ФДТ:

- а – до проведения ФДТ;
- б – после ФДТ;
- в – 4-ые сутки после ФДТ;
- г – через 1 мес после ФДТ

Fig. 2. Endophotographs of tumor stenosis of the esophagus at various times after PDT:

- a – before PDT;
- б – after PDT;
- в – 4th day after PDT;
- г – 1 month after PDT

advanced esophageal cancer with severe malignant dysphagia. The use of PDT allowed for the full effect in 7 (100%) patients in the group with superficial (T1a-T1b) esophageal cancer where PDT was an exclusive treatment method or was combined with previously performed radiation therapy. In the group of patients with stenotic cancer, PDT was effective in 13 (86.7%) patients.

In 3 (20%) of them, the esophageal lumen was completely restored, while in 10 (66.7%) of them, it was partially restored, which enhanced the quality of life and increased the survival duration of this patient population. PDT is also a treatment method chosen for cancer of the upper esophagus since esophageal stenting can cause undesirable subjective sensations.

REFERENCES

1. Korolev M.P., Fedotov L.E., Smirnov A.A., Ogloblin A.L. Endoscopic stenting of stenosing esophageal diseases. Materials of the 14th Russian Gastroenterological Week. Moscow, *Rossiiskii zhurnal gastroenterologii, gepatologii, koloproktologii*, 2008, no. 5, pp. 164–166. (in Russian)
2. Kaprin A. D., Starinsky V. V., Petrova G. V. *Malignant neoplasms in Russia in 2012 (incidence and mortality)* // - М., 2014-P. 250.

ЛИТЕРАТУРА

1. Королев М.П., Федотов Л.Е., Смирнов А.А., Оглоблин А.Л. Эндоскопическое стентирование стенозирующих заболеваний пищевода. Материалы 14-й Российской гастроэнтерологической недели. Москва // *Российский журнал гастроэнтерологии, гепатологии, колопроктологии*. – 2008. – № 5. – С. 164–166.
2. Состояние онкологической помощи населению в 2017 году // под ред. А.Д. Каприна, В.В. Старинского, Г.В. Петровой. – М.:

3. Yoon H.Y., Cheon Y.K., Choi H.J., Shim C.S. Role of Photodynamic Therapy in the Palliation of Obstructing Esophageal Cancer, *Korean J Intern Med*, 2012, vol. 27, no. 3, pp. 278–284. doi: 10.3904/kjim.2012.27.3.278
4. Sokolov V.V., Filonenko E.V., Karпова E.S. Фотодинамическая терапия раннего рака пищевода и желудка *in Photodynamic therapy and photodynamics*. 2014. № 1. С. 58–59. Moscow, pp. 63–69.
5. Stranadko E.F., Mazurin V.S., Shabarov V.L., majors G. A. Endoscopic photodynamic therapy of esophageal cancer // *Photodynamic therapy and photodiagnosis*. 2013. No. 3. P.46.
6. Hatogai K., Yano T., Kojima T., Onozawa M., Daiko H., Nomura S., Yoda Y., Doi T., Kaneko K., Ohtsu A. Salvage photodynamic therapy for local failure after chemoradiotherapy for esophageal squamous cell carcinoma, *Gastrointest Endosc*, 2016, vol. 83, pp.1130–1139.
7. Tanaka T., Matono S., Nagano T., Murata K., Sueyoshi S., Yamana H., Shirouzu K., Fujita H. Photodynamic therapy for large superficial squamous cell carcinoma of the esophagus, *Gastrointest Endosc*, 2011, vol. 73(1), pp. 1–6. doi: 10.1016/j.gie.2010.08.049
8. Lee H.H., Choi M.-G., Hasan T. Application of photodynamic therapy in gastrointestinal disorders: an outdated or re-emerging technique? *Korean J Intern Med*, 2017, vol. 32(1), pp. 1–10.
9. Muto M., Yano T. Photodynamic Therapy for Local Recurrence of Esophageal Cancer after Chemoradiotherapy, *An To Kagaku Ryoho*, 2016, vol. 43, no. 7, pp. 1053–1057.
10. Lee H.H., Choi M.G., Hasan T. Application of photodynamic therapy in gastrointestinal disorders: an outdated or re-emerging technique? *Korean J Intern Med*, 2017, vol. 32, no. 1, pp. 1–10. doi: 10.3904/kjim.2016.200.
11. McCaughan J.S., Photodynamic therapy for obstructive esophageal malignancies, *Diagn. Ther. Endosc.*, 1999, vol. 5, pp. 167–174.
12. Shaoshan H., Qi Z., Wu Y. The inhibiting effect of photodynamic therapy and novel recombinant human endostatin on the in vivo growth of U251 human glioma xenografts, *Tihookeanskii med. zhurnal*, 2013, no. 4, pp. 67–71.
13. Mangiavillano B., Pagano N., Arena M., Miraglia S., Consolo P., Iabichino G., Virgilio C., Luigiano C. Role of stenting in gastrointestinal benign and malignant diseases, *World J Gastrointest Endosc*, 2015, vol. 16, no. 7(5), pp. 460–80. doi: 10.4253/wjge.v7.i5.460
- МНИОИ им. П.А. Герцена – филиал ФГБУ «НМИЦ радиологии» Минздрава России, 2018 г. – 236 с.
3. Yoon H.Y., Cheon Y.K., Choi H.J., Shim C.S. Role of Photodynamic Therapy in the Palliation of Obstructing Esophageal Cancer // *Korean J Intern Med*. – 2012. – Vol. 27, No. 3. – P. 278–284. doi: 10.3904/kjim.2012.27.3.278
4. Соколов В.В., Филоненко Е.В., Карпова Е.С. Фотодинамическая терапия раннего рака пищевода и желудка // Фотодинамическая терапия и фотодиагностика. – 2014. – № 1. – С. 58–59.
5. Странадко Е.Ф., Мазурин В.С., Шабаров В.Л., Майоров Г.А. Эндоскопическая фотодинамическая терапия рака пищевода // Фотодинамическая терапия и фотодиагностика. – 2013. – № 3. – С. 46.
6. Hatogai K., Yano T., Kojima T., et al. Salvage photodynamic therapy for local failure after chemoradiotherapy for esophageal squamous cell carcinoma // *Gastrointest Endosc*. – 2016. – Vol. 83. –P.1130–1139.
7. Tanaka T., Matono S., Nagano T., et al. Photodynamic therapy for large superficial squamous cell carcinoma of the esophagus // *Gastrointest Endosc*. – 2011. – Vol. 73(1). – P. 1–6. doi: 10.1016/j.gie.2010.08.049
8. Lee H.H., Choi M.-G., Hasan T. Application of photodynamic therapy in gastrointestinal disorders: an outdated or re-emerging technique? // *Korean J Intern Med*. – 2017. – Vol. 32(1). – P. 1–10.
9. Muto M., Yano T. Photodynamic Therapy for Local Recurrence of Esophageal Cancer after Chemoradiotherapy // *An To Kagaku Ryoho*. – 2016. – Vol. 43, No. 7. – P. 1053–1057.
10. Lee H.H., Choi M.G., Hasan T. Application of photodynamic therapy in gastrointestinal disorders: an outdated or re-emerging technique? // *Korean J Intern Med*. – 2017. – Vol. 32, No. 1. – P. 1–10. doi: 10.3904/kjim.2016.200.
11. McCaughan J.S., Photodynamic therapy for obstructive esophageal malignancies // *Diagn. Ther. Endosc*. – 1999. – Vol. 5. – P. 167–174.
12. Shaoshan H., Qi Z., Wu Y. The inhibiting effect of photodynamic therapy and novel recombinant human endostatin on the in vivo growth of U251 human glioma xenografts // *Тихоокеанский мед. журнал*. – 2013. – № 4. – С. 67–71.
13. Mangiavillano B., Pagano N., Arena M., et al. Role of stenting in gastrointestinal benign and malignant diseases // *World J Gastrointest Endosc*. – 2015. – Vol. 16, No. 7(5). – P. 460–80. doi: 10.4253/wjge.v7.i5.460